



PATIENT

Trent Canape

SPECIES

Feline

BREED

DSH

SEX

Neutered Male

AGE

14

WEIGHT

13.7

INTERPRETED BY

Eric Lindquist, DMV
DABVP, Cert. IVUSS

**IMAGING
PERFORMED BY**

Charlie Rodriguez

HOSPITAL NAME

Bethany Family PC

REFERRING VET

Kierra Hanrahan

INVOICE

20241

DATE

12/24/22

PRESENTING CLINICAL SIGNS

History: Starting last night has vomited about 10 times. CBC/chem in house was normal. Cat is a major caution so sedation was done today. Rads showed hazy intestines bunched in middle of abdomen looked odd. Urine is yellow but, hazy (hazy ipa) in appearance. O did not feed this morning even tho he wanted to eat. Otherwise nothing new and has been doing ok.

Abnormal PE/Chem/CBC/UA Results: Frequent vomiting.

ULTRASONOGRAPHIC EXAMINATION OF THE ABDOMEN

Urinary System

The **urinary bladder** and visible pelvic urethra were unremarkable for the level of repletion presented. The urine, however, did present some mildly echogenic debris consistent with mucous, exfoliated cells from renal or bladder origin, and/or blood clots as these echogenic changes can all present similarly. This is often related to urinary tract infection but may represent simple evidence of exfoliated debris or sterile inflammation. Cystocentesis, urinalysis, +/- culture would be recommended to rule out and define any UTI. This is a moderate change. The pelvic urethra was imaged 1.0 cm beyond the cystourethral junction.

The **kidneys** revealed largely normal size and structure, corticomedullary definition and ratio (cortex 1/3 of medulla) were essentially maintained with some mild age-related loss of curvilinear patterns regarding the capsule and C/M junction. The cortices presented largely uniform texture with some increased echogenicity expected for his age patient. Medullary structure differed distinctly from that of the cortex and no evidence of pelvic dilation was present. Both kidneys measured 3.9 cm.

Adrenal Glands

Both **adrenal glands** were visualized and recognized as having normal shape, size, position and echogenicity for this breed. The phrenic vasculature, glandular echogenicity and detail were unremarkable. Capsule, cortex, and medullary definition were normal for this age patient.

Spleen

The **spleen** presented a smooth homogeneous parenchyma hyperechoic to liver and renal cortical parenchyma. The capsule was smooth without noticeable expansion or deviation from within the spleen or adjacent pathology. The splenic vasculature demonstrated normal volume without signs of congestion or thrombosis. No sonographic evidence of acute or chronic inflammatory, neoplastic, or infarctual changes were noted.

Liver

The **liver** images from right and left intercostal as well as subcostal views revealed subjectively normal liver size, contour, and structure. Some minor age-related parenchymal remodeling was noted but likely not clinically significant at this time. Vascular and biliary tracts were of normal volume and no evidence of congestion was noted. The gallbladder presented some dependent debris with essentially normal contour. The cystic and common bile ducts were normal. No overt evidence of active inflammatory, infiltrative or regenerative pathology was noted but should be paired with current or past LE elevations regarding any clinical significance to this presentation. The hepatic lymph nodes were unremarkable.



PATIENT

Trent Canape

SPECIES

Feline

BREED

DSH

SEX

Neutered Male

AGE

14

WEIGHT

13.7

INTERPRETED BY

Eric Lindquist, DMV
DABVP, Cert. IVUSS

IMAGING PERFORMED BY

Charlie Rodriguez

HOSPITAL NAME

Bethany Family PC

REFERRING VET

Kierra Hanrahan

INVOICE

20241

DATE

12/24/22

Gastrointestinal

The **gastrointestinal** presentation revealed mild uniform prominence of the gastric mucosa as well as areas of "ropey" small intestinal wall with slight disruption of the normal 1:3 muscularis/mucosal ratio. The intestinal submucosa was slightly irregular, thickened and hyperechoic suggestive of low grade, chronic disease. No concerning lymphadenopathy was visible. No evidence of obstruction was present. Chronic inflammatory bowel disease is likely with a low possibility of an early neoplastic event such as lymphoma. Full thickness tissue biopsies via open laparotomy, ideally guided by intraoperative ultrasound in order to obtain the most representative mural sample, would be necessary to rule out this possibility. A minor amount of gastric fluid was present. This is a mild change. No neoplastic criteria were met. A portion of intestine did lose mural detail, surrounded by slight lymph node enlargement, measuring 1.0 cm with reactive surrounding mesentery.

Pancreas

The base and limbs of the **pancreas** were observed to be largely isoechoic to surrounding omental fat. Pancreatic duct and capsular contour were acceptably normal and parenchyma respected normal curvilinear patterns. No overt evidence of active inflammatory or neoplastic disease was noted.

Free Abdomen

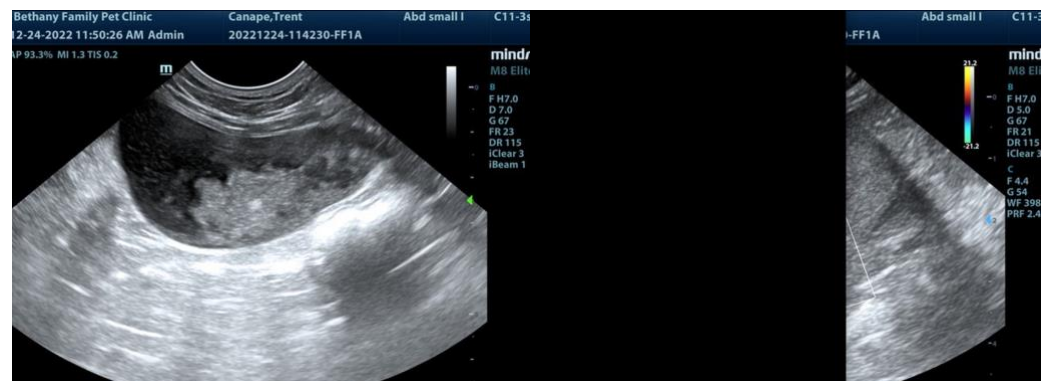
The mesenteric **lymph nodes** were slightly enlarged and mildly irregular.

ULTRASONOGRAPHIC FINDINGS

- Diffuse intestinal thickening with focal region of concern for possible emerging neoplasia.
- Reactive mesentery
- Slightly enlarged and mildly irregular mesenteric lymph nodes
- Urinary bladder debris
- Age-related renal and hepatic changes

INTERPRETATION OF THE FINDINGS & FURTHER RECOMMENDATIONS

Surgical exploratory with full thickness biopsies in the distal jejunum is recommended for further definition. There is a possibility of emerging round cell neoplasia versus acute on chronic inflammatory bowel.





PATIENT

Trent Canape

SPECIES

Feline

BREED

DSH

SEX

Neutered Male

AGE

14

WEIGHT

13.7

INTERPRETED BY

Eric Lindquist, DMV
DABVP, Cert. IVUSS

IMAGING PERFORMED BY

Charlie Rodriguez

HOSPITAL NAME

Bethany Family PC

REFERRING VET

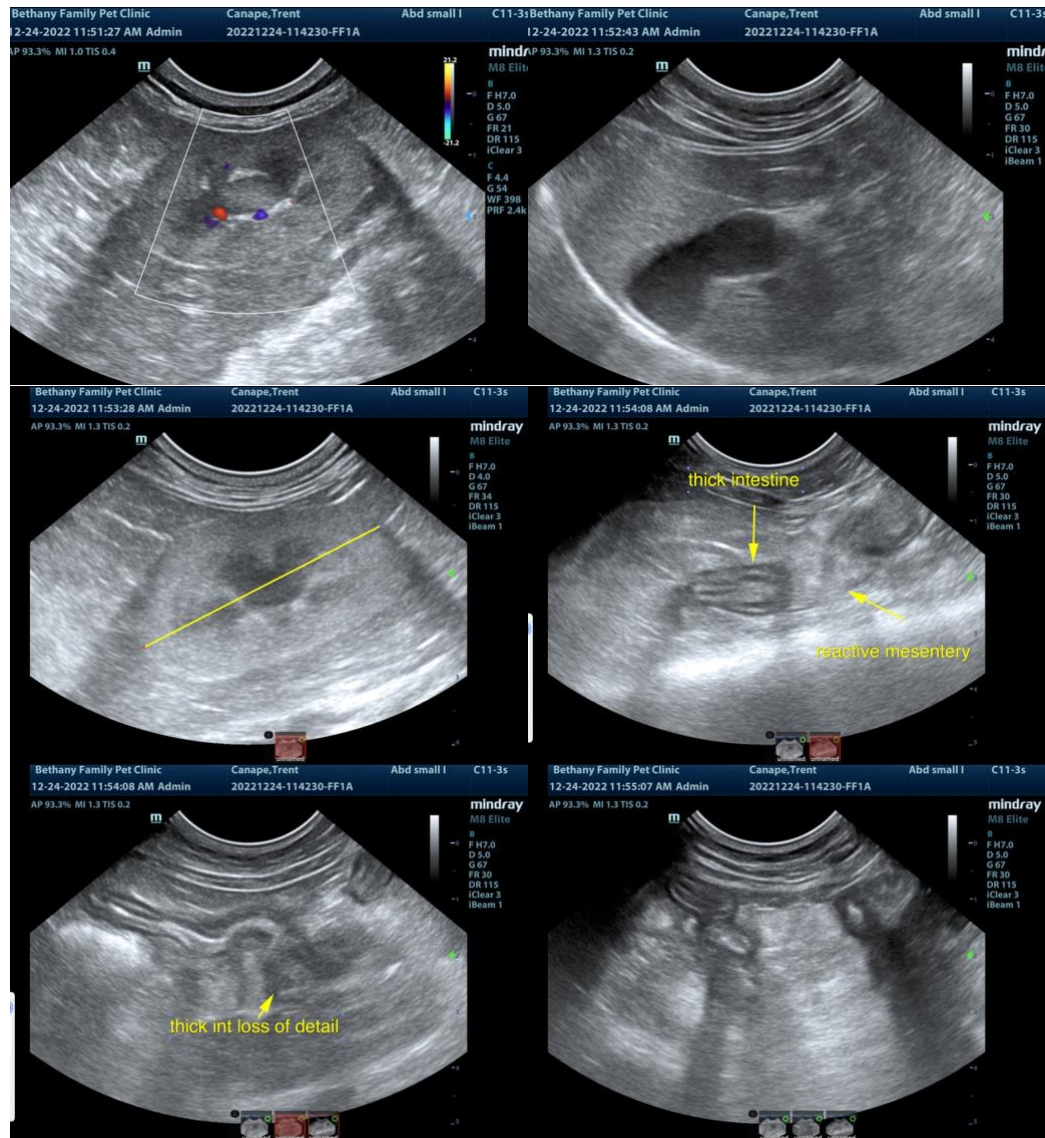
Kierra Hanrahan

INVOICE

20241

DATE

12/24/22



The information and recommendations provided are based on the images presented by the referring veterinarian. No evaluation can be communicated regarding pathology that was not visible in the image/video clips provided.

Thank you for this referral. If the clinical or image interpretation does not parallel your findings or if I can be of any further assistance please contact me.

Eric Lindquist, DMV, DABVP, Cert. IVUSS, CEO of SonoPath.com
info@SonoPath.com